



OPEN ACCESS

Revisiting the vicious circle of dry eye disease: a focus on the pathophysiology of meibomian gland dysfunction

Christophe Baudouin,^{1,2} Elisabeth M Messmer,³ Pasquale Aragona,⁴ Gerd Geerling,⁵ Yonca A Akova,⁶ José Benítez-del-Castillo,⁷ Kostas G Boboridis,⁸ Jesús Merayo-Llodes,⁹ Maurizio Rolando,¹⁰ Marc Labetoulle¹¹

For numbered affiliations see end of article.

Correspondence to

Professor Christophe Baudouin, Quinze-Vingts National Ophthalmology Hospital, 28 rue de Charenton, Paris 75012, France; cbaudouin@15-20.fr

Received 30 June 2015

Revised 29 October 2015

Accepted 28 November 2015

Published Online First

18 January 2016

ABSTRACT

Meibomian gland dysfunction (MGD) is the most frequent cause of dry eye disease (DED). Eyelid inflammation, microbial growth, associated skin disorders as well as potentially severe corneal complications culminate to make MGD a complex multifactorial disorder. It is probable that MGD is a heterogeneous condition arising from any combination of the following five separate pathophysiological mechanisms: eyelid inflammation, conjunctival inflammation, corneal damage, microbiological changes and DED resulting from tear film instability. The pathogenesis of both MGD and DED can be described in terms of a 'vicious circle': the underlying pathophysiological mechanisms of DED and MGD interact, resulting in a double vicious circle. The MGD vicious circle is self-stimulated by microbiological changes, which results in increased melting temperature of meibum and subsequent meibomian gland blockage, reinforcing the vicious circle of MGD. Meibomian gland blockage, dropout and inflammation directly link the two vicious circles. MGD-associated tear film instability provides an entry point into the vicious circle of DED and leads to hyperosmolarity and inflammation, which are both a cause and consequence of DED. Here we propose a new pathophysiological scheme for MGD in order to better identify the pathological mechanisms involved and to allow more efficient targeting of therapeutics. Through better understanding of this scheme, MGD may gain true disease status rather than being viewed as a mere dysfunction.

determined, in 2011 the International Workshop on MGD proposed the following definition for MGD: "a chronic, diffuse abnormality of the meibomian glands, commonly characterised by terminal duct obstruction and/or qualitative/quantitative changes in the glandular secretion. It may result in alteration of the tear film, symptoms of eye irritation, clinically apparent inflammation, and ocular surface disease".¹¹ The International Workshop on MGD successfully marshalled a large literature base into an exhaustive scheme of the mechanisms underlying the pathogenesis of MGD and the numerous interacting pathways involved.¹ However, the complexity of this scheme may limit its relevance in clinical practice. Here we introduce a new pathological scheme of MGD, which may be easier to interpret in clinical practice, to facilitate the understanding of the mechanisms that underlie its development and relationship with DED and to allow more efficient treatment of both MGD and DED.

PREVALENCE OF MGD

Within the general population, precise estimates of MGD prevalence are elusive as rates vary geographically and, until recently, a clear definition of MGD was lacking. The prevalence of MGD varies considerably in published studies.^{12–16} Generally, it is higher in Asian populations, ranging from 46% to 70%, whereas in Caucasian populations the MGD prevalence ranges from 3.5% to 20%.¹¹ It should be noted that the higher prevalence of MGD in Asian populations is partly due to inconsistent diagnostic criteria among countries.¹⁷ For example, the Beijing study included both the clinical signs and the symptoms of MGD in their definition whereas other studies did not.⁷ Moreover, certain diagnostic criteria may be unable to distinguish between MGD and aqueous deficient DED, which may also point towards a strong relationship between the two diseases.¹⁸ The International Workshop on MGD suggests establishing a set of MGD-specific symptoms to aid in diagnosis.⁷ The prevalence of MGD is also affected by age, with older patients at increased risk of developing MGD. In a group of patients aged <30 years and ≥60 years, 33% and 72% had MGD, respectively.¹⁹ Prevalence rates also increase if the mixed forms of DED, which include MGD and aqueous tear deficiency, are considered.²⁰

INTRODUCTION

The meibomian glands, found in the upper and lower eyelids, excrete lipids onto the ocular surface that forms the outermost layer of the tear film, lubricating the ocular surface during blinking and protecting against tear evaporation.^{1–2} Through dysfunction of the meibomian glands, reduced lipid secretion may contribute to tear film instability and entry into the vicious circle of dry eye disease (DED).^{3–6} Indeed, meibomian gland dysfunction (MGD) is the most common cause of evaporative DED^{7–8} and is found even in situations previously considered to be primary (pure) aqueous-deficient DED.⁹ Moreover, MGD is correlated with ocular discomfort during activities requiring relevant visual tasks, such as the use of video display terminals.¹⁰ Although the precise aetiology and pathophysiology of MGD remain to be



Open Access
Scan to access more
free content



CrossMark

To cite: Baudouin C, Messmer EM, Aragona P, et al. *Br J Ophthalmol* 2016;**100**:300–306.

CLASSIFICATION AND AETIOLOGY OF MGD

According to the report of the Definition and Classification Subcommittee of the International Workshop on MGD, MGD may be classified as a low- or high-delivery state, according to the extent of meibomian lipid secretion.²¹ The low-delivery state, which is the most common form of MGD, is associated with deficiencies in meibomian secretion, and it may be further characterised as obstructive, with cicatricial and non-cicatricial subcategories, or hyposecretory.²¹ Hyposecretory MGD is associated with gland atrophy. Obstructive MGD is the most prevalent form of low-delivery state MGD and is caused by hyperkeratinisation, which is influenced by sex, hormonal disturbances, topical medications and age.²¹ Interestingly, emerging evidence from both animal and human studies suggests that age-related cell signalling changes within the meibomian gland can lead to gland atrophy,^{22 23} suggesting that some cases of age-related MGD could be classified as hyposecretory rather than obstructive MGD.

Increased meibum viscosity, which is present in all cases of obstructive MGD, may arise because of changes in meibum composition.²¹ High-delivery state MGD, also known as hypersecretory MGD, is characterised by the release of large amounts of meibum at the lid margin in response to pressure on the eyelids. Hypersecretory MGD has been associated with seborrhoeic dermatitis in 100% of cases, but it may also be associated with rosacea.^{8 21} In both hyposecretory and hypersecretory MGD, the lipids produced are modified (non-canonical), changing the composition and reducing the quality of the tear film, thus leading to symptoms of eye irritation, inflammation and DED.¹¹ Although exhaustive, the complexity of the aetiological classification and associated pathological scheme proposed by the International Workshop on MGD may be difficult to interpret in clinical practice as both rare (eg, genetic atrophy of meibomian glands) and more common mechanisms (eg, rosacea) are included at the same level.

Multiple causes may be responsible for the development of MGD-associated tear film alterations, including eye surgery or systemic hormonal treatments such as oestrogen replacement therapy in women and anti-androgen therapy in men.¹ The latter suggests that hormonal changes contribute to the aetiology of MGD.⁸ Moreover, ophthalmic factors such as aniridia, proliferation of *Demodex folliculorum*, eyelid tattooing, floppy eyelid syndrome, giant papillary conjunctivitis and trachoma are also believed to correlate with MGD.⁸

IDENTIFYING THE PATHOPHYSIOLOGICAL MECHANISMS OF MGD

MGD is associated with multiple pathological mechanisms including inflammation, microbial factors and lipid deficiencies.¹ Eyelid inflammation, microbiological proliferation, release of toxic cytokines onto the cornea and hyper-evaporation combine to create a picture of a benign dysfunction. However, this is often painful and dangerous to the cornea when inflammatory infiltrates, phlyctens, keratitis or peripheral ulcers complicate the meibomitis.⁸ With such variable and complex mechanisms involved in MGD, analysing the pathology and even defining the disease is challenging. Is MGD a disease of the eyelids, tear film, cornea or the entire ocular surface? Moreover, are the associated microbial, metabolic, inflammatory or endocrine diseases related to the eye or the skin? The International Workshop on MGD chose to focus on DED as a consequence of MGD but did not consider meibomitis or eyelid or corneal

changes; therefore, the pathophysiology of MGD was not fully resolved.²⁴

In our scheme, the stasis of the meibum, which may be caused by obstruction, dropout or inflammation of the meibomian gland, can promote the growth of bacteria. This may then increase the release of esterases and lipases by commensal bacteria of the eyelids. As a consequence of this increased enzyme activity, bacteria can change the viscosity of the meibum, leading to further stasis of the meibum within the meibomian glands, and generate free fatty acids, which in turn causes inflammation and hyperkeratinisation.^{1 5} These changes in lipid composition may determine the occurrence of foam in the tear film, often visible on the lid margin of patients with MGD.^{25 26}

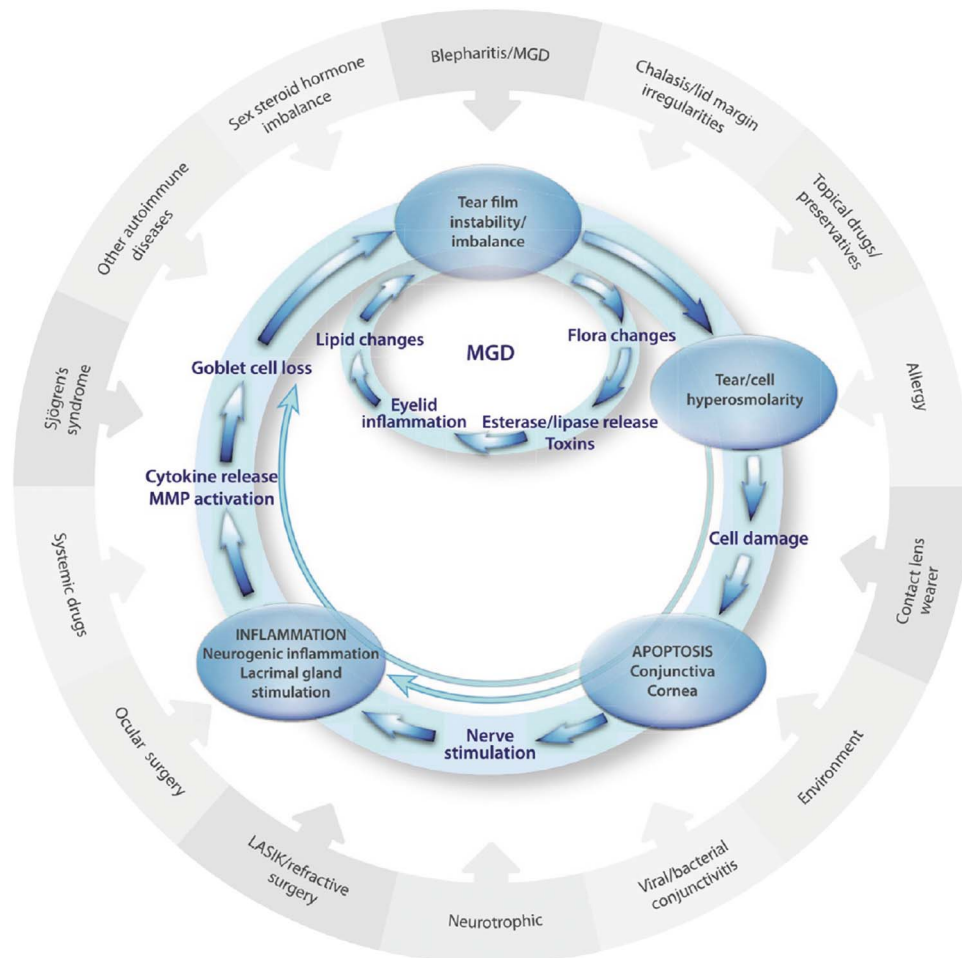
Although a critical analysis of the literature on age-related MGD is beyond the scope of this review, age has been associated with specific pathogenic effects on meibomian gland structure, such as altered localisation of the peroxisome proliferator-activated receptor gamma, a lipid-activated hormone receptor that regulates lipid synthesis and cell differentiation,^{23 27} or meibomian gland atrophy through a loss of MGD progenitors.²² Additionally, accumulation of reactive oxygen species with age may play a role in the pathogenesis of MGD.²⁸ These mechanisms may underlie atrophic non-obstructive MGD in the older population.²⁹ Although the pathophysiology of age-related MGD may be distinct from non-age-related MGD, subsequent meibomian gland dropout²⁹ may allow entry into the vicious circle of MGD.

It is likely that MGD is a heterogeneous complex condition arising from any combination of the following five separate pathophysiological mechanisms: eyelid inflammation, conjunctival inflammation, corneal damage, microbiological changes and tear film instability-associated DED. The International Workshop on MGD proposed a complex pathway involved in the self-enforcing vicious circles of MGD (figure 1).²¹ Although these proposed pathways are probably correct, they may be too focused on DED as a final consequence of MGD to be of real practical application. We therefore present the previously published vicious circle of DED,³ illustrating its various entry points, and then we build on this to develop the double vicious circle that demonstrates the interacting pathophysiologicals of MGD and DED.

VICIOUS CIRCLE OF DED

In 2007 and 2013 we proposed new patterns for understanding DED (figure 2).^{3 6} Tear film instability, tear hyperosmolarity, apoptosis and inflammation contribute to the pathophysiology of DED. These aetiologies are not mutually exclusive, but rather connected to one another in a cyclical manner, acting as entry points into the vicious circle of DED. As such, DED may be described as an autonomous self-sustaining disease state that is progressively disconnected from its initial causes. In the vicious circle, rapid break-up of the tear film after blinking (tear film instability) leads to local drying and hyperosmolarity of the epithelial surface. In turn, this leads to apoptosis, inflammation and a loss of mucin-producing goblet cells. This cascade of mechanisms, involving osmotic, mechanical and inflammatory stress, destroys goblet cells and defence systems of the ocular surface leading to further damage of the tear film, and thus closes the circle. A major cause such as Sjögren's syndrome can stimulate all states of the vicious circle. Other factors such as corneal surgery, low humidity and high airflow, contact lens wear, allergies or preservatives may disrupt reflex tear delivery to the ocular surface or increase tear film instability, thus initiating entry into the vicious circle.⁵

Figure 2 Proposed vicious circle of the pathology of dry eye disease. MGD, meibomian gland dysfunction.



inflammation of the eyelid and lacrimal effects was identified based on the observation that exposure of ocular surface epithelia to desiccating stress led to the release of cornified envelope precursors by the ocular epithelium.⁴² This was accompanied by keratinisation of meibomian gland orifices, which caused further meibomian gland blockade and atrophy as well as loss of mucin-filled goblet cells and entrapment of mucin within the remaining goblet cells, blocking delivery of mucin to the ocular surface and contributing to the development of DED.⁴² Keratinisation of meibomian glands is believed to arise from hyperosmolarity and inflammatory cytokine-induced expression of corneal envelope precursors.^{43–44} Other pathogenic mechanisms associated with DED include increased age and the use of benzalkonium chloride-containing glaucoma medications.^{13–15–46} Meibomian gland blockage, dropout and inflammation directly link the DED and MGD vicious circles.

Although MGD is the most common cause of evaporative DED,^{7–8} Bron *et al*⁴¹ proposed an additional hypothesis where MGD-associated DED leads to a compensatory increase in tear production, followed by compromised lacrimal function and reduced tear secretion that leads to a mixed form of DED comprised of both evaporative and aqueous subtypes.⁴¹ Support for this hypothesis has been recently published; fluorescein score, tear film break-up time and Schirmer test scores were significantly worse in patients with aqueous-deficient DED compared with MGD, suggesting that increased tear production may compensate, at least for a while, for meibomian gland loss in

patients with early-stage MGD.⁴⁷ This hypothesis illustrates how all ocular surface components are inter-related.

Imaging techniques such as *in vivo* confocal microscopy (IVCM), optical coherence tomography and keratography allow visualisation of the cellular and anatomical structures of the cornea and ocular surface.^{48–50} These techniques can therefore provide valuable information on the relationship between DED and MGD.⁵¹ Infrared imaging revealed an increased meibomian gland dropout score in patients with Sjögren's syndrome compared with control subjects without DED,⁴⁹ suggesting that patients with Sjögren's syndrome may be at a greater risk of developing MGD. Moreover, IVCM revealed that the meibomian glands of patients with Sjögren's syndrome had higher acinar density, smaller diameters, a greater density of periglandular inflammatory cells and higher secretion reflectivity compared with patients with MGD.⁵¹ These observations support an essential role of MGD in DED and could provide a histopathological basis for the previously mentioned mixed form of aqueous and evaporative DED. Additionally, in a retrospective observational pilot study of patients with MGD-associated refractory DED, IVCM revealed clinically non-apparent inflammation of the palpebral conjunctiva despite improvements in tear film break-up time, an increased number of meibomian glands yielding secretion and a normal clinical examination post-treatment, suggesting that IVCM may also be a useful tool for identifying the underlying causes of symptom-sign disparity in patients with MGD.⁵² Further studies are needed to truly

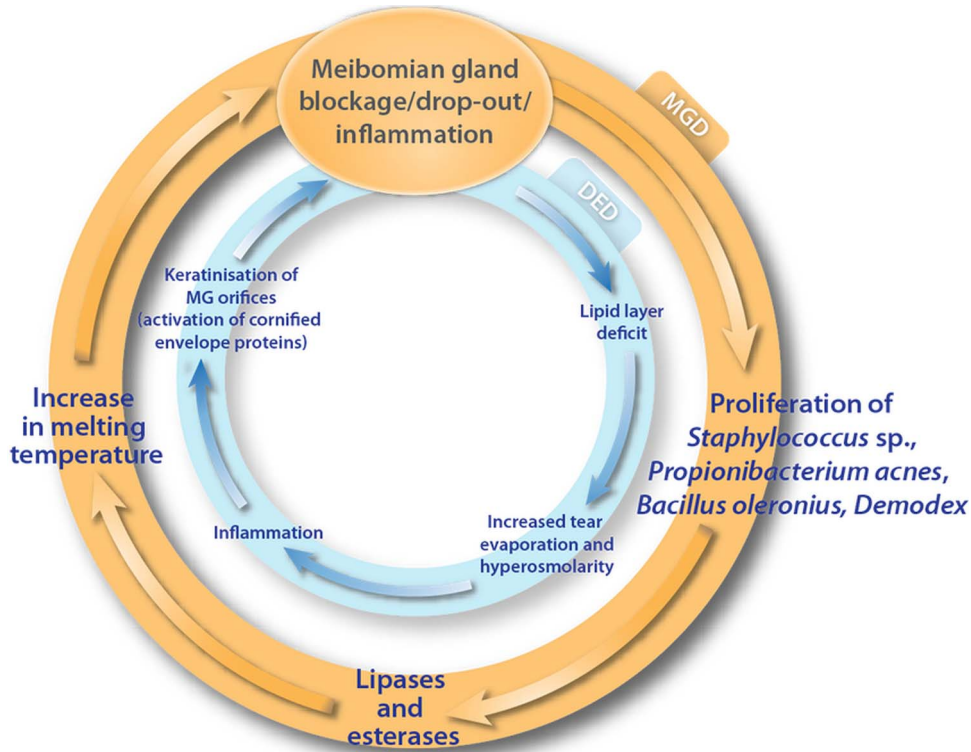


Figure 3 Importance of meibomian gland dysfunction in the vicious circle of the pathology of dry eye disease.⁶¹

understand how imaging can advance our understanding of the relationship between MGD and DED.

WHAT IS THE PURPOSE OF THIS NEW DOUBLE VICIOUS CIRCLE?

Beyond its educational and scientific interest, the double vicious circle may be used for understanding and revealing the

complexity of the pathophysiological mechanisms underlying DED and MGD, as well as a tool to focus and guide therapy. **Figure 4** illustrates how different therapies, some acting at multiple points of the circle, may be used to disrupt the vicious circles of MGD and DED. Eyelid hygiene, consisting of eyelid warming and massage, reduces the proliferation of bacteria that are believed to increase the melting temperature of meibum, in

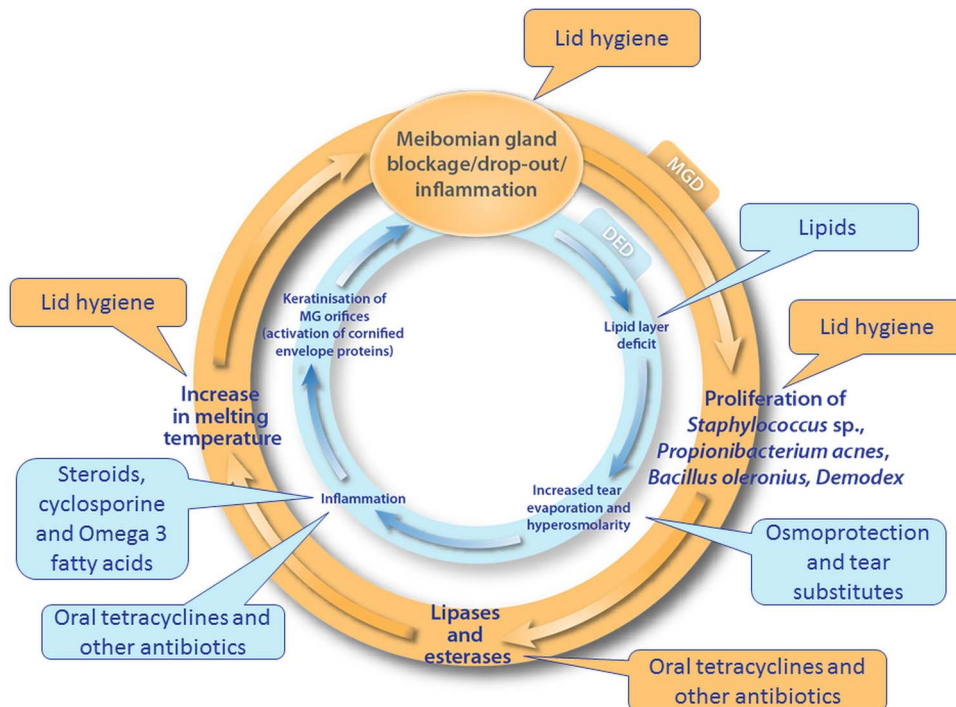


Figure 4 Different therapies may target particular pathophysiological mechanisms that underlie the vicious circle of dry eye disease.

addition to melting the altered meibomian lipids to improve their secretion.^{35 53} Eyelid hygiene devices such as the MGDRx Eyebag (The Eyebag Company, West Yorkshire, UK), Blephasteam (Laboratoires Théa, Clermont-Ferrand, France) and LipiFlow (TearScience, North Carolina, USA) have been shown to improve symptoms in patients with MGD.^{54–57} The anti-inflammatory and antimicrobial effects of oral tetracycline derivatives such as doxycycline, and antibiotics, including azithromycin, may reduce bacterial proliferation and prevent inflammation-induced keratinisation of meibomian glands to improve meibum secretion.^{35 58 59} Moreover, figure 4 illustrates how therapies that have the potential to break one of the vicious circles, such as tear substitutes, may impact on the other via indirect effects on meibomian gland blockage, dropout and inflammation.

It seems apparent that a diagnosis of MGD is based on a set of signs and symptoms and that its true nosology remains to be determined. The double vicious circle scheme defined here creates the foundation for the classification of MGD; it highlights the pathophysiological mechanisms involved and addresses the basics of treatment. Taken together, this new scheme perhaps gives MGD true disease status and identifies it as more than a simple dysfunction.

Author affiliations

¹Quinze-Vingts National Ophthalmology Hospital, University Versailles St Quentin en Yvelines, Versailles, France

²UPMC Univ Paris 06, UMR_S 968, Institut de la Vision, Paris, France

³Department of Ophthalmology, Ludwig Maximilian University, Munich, Germany

⁴Institute of Ophthalmology, University of Messina, Messina, Italy

⁵Department of Ophthalmology, University Hospital Düsseldorf, Heinrich-Heine University, Düsseldorf, Germany

⁶Department of Ophthalmology, Bayindir Hospital, Ankara, Turkey

⁷San Carlos University Hospital, Complutense University, Madrid, Spain

⁸Department of Ophthalmology, Aristotle University of Thessaloniki, Thessaloniki, Greece

⁹University of Oviedo and Fernández-Vega Ophthalmological Institute, Oviedo, Spain

¹⁰Department of Neuroscience, Ophthalmology, and Genetics, University of Genoa, Genoa, Italy

¹¹Ophthalmology Department, Bicêtre University Hospital, Le Kremlin-Bicêtre, France

Twitter Follow Kostas Boboridis at @KBoboridis

Acknowledgements The authors thank Newton Healthcare Communications for writing and editorial support, which was funded by Allergan, UK.

Contributors CB defined the concept and scope of the review. EMM, PA, GG, YAA, JBdC, KGB, JM-L, MR and ML provided critical review of the manuscript. All of the authors were involved in the finalisation of the manuscript.

Funding Allergan provided funding for the meetings and for the development of this manuscript. The authors were involved with the entire process, from design to critical revision of the manuscript, and maintained complete control over the direction and content of the paper.

Competing interests CB has received research grants and consulting fees from Alcon, Allergan, Santen and Théa. EMM has acted as an advisor and presenter for Allergan, Alcon, Bausch & Lomb, Cromapharma, MSD, Oculus, Santen, Théa and Ursapharm. PA has acted as a consultant and presenter for Allergan, Alcon Italy, Bausch & Lomb, Santen, Medivis, Théa, Eupharmed and Farmigea and has received a research grant from SOOFT Italia. GG has acted as a consultant or speaker for Allergan, Alcon, Bausch & Lomb, Chiesi, Oculus, Santen, Théa, TearLab and TearScience. YAA has acted as an advisor and presenter for Allergan, Théa, Bausch & Lomb, and Alcon. JBdC has acted as a consultant for Allergan, Bausch & Lomb, Théa, Alcon and Santen. KGB declares financial relationships with Allergan, Alcon and Théa. MR declares financial relationships with Allergan, Bausch & Lomb, Farmigea, Théa, Alcon, Eupharma, Santen/Novagali and Alfalntes. JM-L has received research grants from Théa and has acted as a consultant for Allergan. ML has acted as a consultant for Allergan, Alcon, Bausch & Lomb, Farmigea, MSD, Santen/Novagali and Théa.

Provenance and peer review Not commissioned; externally peer reviewed.

Open Access This is an Open Access article distributed in accordance with the Creative Commons Attribution Non Commercial (CC BY-NC 4.0) license, which

permits others to distribute, remix, adapt, build upon this work non-commercially, and license their derivative works on different terms, provided the original work is properly cited and the use is non-commercial. See: <http://creativecommons.org/licenses/by-nc/4.0/>

REFERENCES

- Knop E, Knop N, Millar T, et al. The International Workshop on Meibomian Gland Dysfunction: report of the Subcommittee on Anatomy, Physiology, and Pathophysiology of the Meibomian Gland. *Invest Ophthalmol Vis Sci* 2011;52:1938–78.
- McCulley JP, Shine WE. Meibomian gland function and the tear lipid layer. *Ocul Surf* 2003;1:97–106.
- Baudouin C, Aragona P, Messmer EM, et al. Role of hyperosmolarity in the pathogenesis and management of dry eye disease: proceedings of the OCEAN group meeting. *Ocul Surf* 2013;11:246–58.
- Rolando M, Papadia M. Diagnosis and management of the lid and ocular surface disorders. In: Asbell PA, Lemp MA, eds. *Dry eye disease: the clinician's guide to diagnosis and treatment*. New York: Thieme Medical Publishers, 2006:63–83.
- International Dry Eye Workshop. Report of the International Dry Eye Workshop (DEWS). *Ocul Surf* 2007;5:61–204.
- Baudouin C. [A new approach for better comprehension of diseases of the ocular surface]. *J Fr Ophthalmol* 2007;30:239–46.
- Schaumberg DA, Nichols JJ, Papas EB, et al. The International Workshop on Meibomian Gland Dysfunction: report of the subcommittee on the epidemiology of, and associated risk factors for, MGD. *Invest Ophthalmol Vis Sci* 2011;52:1994–2005.
- Foulks GN, Nichols KK, Bron AJ, et al. Improving awareness, identification, and management of meibomian gland dysfunction. *Ophthalmology* 2012;119:S1–12.
- Lemp MA, Foulks GN, Pepose JS. Evaluation of tear osmolarity in non-Sjogren and Sjogren syndrome dry eye patients with the TearLab system. *Cornea* 2013;32:379–81.
- Fenga C, Aragona P, Cacciola A, et al. Meibomian gland dysfunction and ocular discomfort in video display terminal workers. *Eye* 2008;22:91–5.
- Nichols KK, Foulks GN, Bron AJ, et al. The International Workshop on Meibomian Gland Dysfunction: Executive Summary. *Invest Ophthalmol Vis Sci* 2011;52:1922–9.
- Uchino M, Dogru M, Yagi Y, et al. The features of dry eye disease in a Japanese elderly population. *Optom Vis Sci* 2006;83:797–802.
- Schein OD, Munoz B, Tielsch JM, et al. Prevalence of dry eye among the elderly. *Am J Ophthalmol* 1997;124:723–8.
- McCarty CA, Bansal AK, Livingston PM, et al. The epidemiology of dry eye in Melbourne, Australia. *Ophthalmology* 1998;105:1114–19.
- Lekhanont K, Rojanaporn D, Chuck RS, et al. Prevalence of dry eye in Bangkok, Thailand. *Cornea* 2006;25:1162–7.
- Lin PY, Tsai SY, Cheng CY, et al. Prevalence of dry eye among an elderly Chinese population in Taiwan: the Shihpai Eye Study. *Ophthalmology* 2003;110:1096–101.
- Viso E, Rodriguez-Ares MT, Abelenda D, et al. Prevalence of asymptomatic and symptomatic meibomian gland dysfunction in the general population of Spain. *Invest Ophthalmol Vis Sci* 2012;53:2601–6.
- Arita R, Itoh K, Maeda S, et al. Efficacy of diagnostic criteria for the differential diagnosis between obstructive meibomian gland dysfunction and aqueous deficiency dry eye. *Jpn J Ophthalmol* 2010;54:387–91.
- Staneck S. Meibomian gland status comparison between active duty personnel and U.S. veterans. *Mil Med* 2000;165:591–3.
- Tong L, Chaurasia SS, Mehta JS, et al. Screening for meibomian gland disease: its relation to dry eye subtypes and symptoms in a tertiary referral clinic in Singapore. *Invest Ophthalmol Vis Sci* 2010;51:3449–54.
- Nelson JD, Shimazaki J, Benitez-del-Castillo JM, et al. The International Workshop on Meibomian Gland Dysfunction: report of the Definition and Classification Subcommittee. *Invest Ophthalmol Vis Sci* 2011;52:1930–7.
- Parfitt GJ, Xie Y, Geyfman M, et al. Absence of ductal hyper-keratinization in mouse age-related meibomian gland dysfunction (ARMGD). *Aging (Albany NY)* 2013;5:825.
- Nien CJ, Massei S, Lin G, et al. Effects of age and dysfunction on human meibomian glands. *Arch Ophthalmol* 2011;129:462–9.
- Foulks GN, Bron AJ. Meibomian gland dysfunction: a clinical scheme for description, diagnosis, classification, and grading. *Ocul Surf* 2003;1:107–26.
- Lozato PA, Pisella PJ, Baudouin C. [The lipid layer of the lacrimal tear film: physiology and pathology]. *J Fr Ophthalmol* 2001;24:643–58.
- Borchman D, Foulks GN, Yappert MC, et al. Human meibum lipid conformation and thermodynamic changes with meibomian-gland dysfunction. *Invest Ophthalmol Vis Sci* 2011;52:3805.
- Nien CJ, Paugh JR, Massei S, et al. Age-related changes in the meibomian gland. *Exp Eye Res* 2009;89:1021–7.
- Ibrahim OM, Dogru M, Matsumoto Y, et al. Oxidative stress induced age dependent meibomian gland dysfunction in Cu, Zn-superoxide dismutase-1 (Sod1) knockout mice. *PLoS ONE* 2014;9:e99328.

- 29 Villani E, Canton V, Magnani F, *et al.* The aging meibomian gland: an in vivo confocal study. *Invest Ophthalmol Vis Sci* 2013;54:4735–40.
- 30 Labetoulle M, Baudouin C. From pathogenic considerations to a simplified decision-making schema in dry eye disease. *J Fr Ophthalmol* 2013;36:543–7.
- 31 Hamano T, Horimoto K, Lee M, *et al.* Sodium hyaluronate eyedrops enhance tear film stability. *Jpn J Ophthalmol* 1996;40:62–5.
- 32 Nakamura M, Hikida M, Nakano T, *et al.* Characterization of water retentive properties of hyaluronan. *Cornea* 1993;12:433–6.
- 33 Simmons PA, Chang-Lin J-E, Chung Q, *et al.* Effect of compatible solutes on transepithelial electrical resistance and uptake in primary rabbit corneal epithelial cell layers model. Presented at the Association for Research in Vision and Ophthalmology (ARVO), 2007.
- 34 Bayhan SA, Bayhan HA, Muhafiz E, *et al.* Effects of osmoprotective eye drops on tear osmolarity in contact lens wearers. *Can J Ophthalmol* 2015;50:283–9.
- 35 Geerling G, Tauber J, Baudouin C, *et al.* The International Workshop on Meibomian Gland Dysfunction: report of the Subcommittee on Management and Treatment of Meibomian Gland Dysfunction. *Invest Ophthalmol Vis Sci* 2011;52:2050–64.
- 36 Qiao J, Yan X. Emerging treatment options for meibomian gland dysfunction. *Clin Ophthalmol* 2013;7:1797–803.
- 37 Kosik-Bogacka DI, Lanocha N, Lanocha A, *et al.* Role of Demodex folliculorum in the pathogenesis of blepharitis. *Acta Ophthalmol* 2012;90:e579.
- 38 Murillo N, Aubert J, Raoult D. Microbiota of Demodex mites from rosacea patients and controls. *Microb Pathog* 2014;71–72:37–40.
- 39 Chang M, Lee H, Park MS, *et al.* The clinical characteristics and new classification of sticky eyelid syndrome in East Asian patients. *Acta Ophthalmol* 2014;92:e667–70.
- 40 Alvarenga LS, Mannis MJ. Ocular rosacea. *Ocul Surf* 2005;3:41–58.
- 41 Bron AJ, Yokoi N, Gafney E, *et al.* Predicted phenotypes of dry eye: proposed consequences of its natural history. *Ocul Surf* 2009;7:78–92.
- 42 Corrales RM, de Paiva CS, Li DQ, *et al.* Entrapment of conjunctival goblet cells by desiccation-induced cornification. *Invest Ophthalmol Vis Sci* 2011;52:3492–9.
- 43 Takahashi H, Asano-Kato N, Nakamura S, *et al.* Interferon-gamma-dependent stimulation of human involucrin gene expression: STAT1 (signal transduction and activators of transcription 1) protein activates involucrin promoter activity. *Biochem J* 1999;334:797–802.
- 44 Chen Z, Tong L, Li Z, *et al.* Hyperosmolarity-induced cornification of human corneal epithelial cells is regulated by JNK MAPK. *Invest Ophthalmol Vis Sci* 2008;49:539–49.
- 45 Schein OD, Hochberg MC, Munoz B, *et al.* Dry eye and dry mouth in the elderly: a population-based assessment. *Arch Intern Med* 1999;159:1359–63.
- 46 Pisella PJ, Pouliquen P, Baudouin C. Prevalence of ocular symptoms and signs with preserved and preservative free glaucoma medication. *Br J Ophthalmol* 2002;86:418–23.
- 47 Arita R, Morishige N, Koh S, *et al.* Increased tear fluid production as a compensatory response to meibomian gland loss: a multicenter cross-sectional study. *Ophthalmology* 2015;122:925–33.
- 48 Qazi Y, Aggarwal S, Hamrah P. Image-guided evaluation and monitoring of treatment response in patients with dry eye disease. *Graefes Arch Clin Exp Ophthalmol* 2014;252:857–72.
- 49 Menzies KL, Srinivasan S, Prokopich CL, *et al.* Infrared imaging of meibomian glands and evaluation of the lipid layer in Sjögren's syndrome patients and nondry eye controls. *Invest Ophthalmol Vis Sci* 2015;56:836–41.
- 50 Ban Y, Ogawa Y, Ibrahim OM, *et al.* Morphologic evaluation of meibomian glands in chronic graft-versus-host disease using in vivo laser confocal microscopy. *Mol Vis* 2011;17:2533.
- 51 Villani E, Beretta S, De CM, *et al.* In vivo confocal microscopy of meibomian glands in Sjögren's syndrome. *Invest Ophthalmol Vis Sci* 2011;52:933–9.
- 52 Qazi Y, Kheirkhah A, Blackie C, *et al.* In vivo detection of clinically non-apparent ocular surface inflammation in patients with meibomian gland dysfunction-associated refractory dry eye symptoms: a pilot study. *Eye* 2015;29:1099–110.
- 53 Gao YY, Di Pascuale MA, Li W, *et al.* In vitro and in vivo killing of ocular Demodex by tea tree oil. *Br J Ophthalmol* 2005;89:1468–73.
- 54 Bilkhu PS, Naroo SA, Wolffsohn JS. Randomised masked clinical trial of the MGDRx eyebag for the treatment of meibomian gland dysfunction-related evaporative dry eye. *Br J Ophthalmol* 2014;98:1707–11.
- 55 Benitez Del Castillo JM, Kaercher T, Mansour K, *et al.* Evaluation of the efficacy, safety, and acceptability of an eyelid warming device for the treatment of meibomian gland dysfunction. *Clin Ophthalmol* 2014;8:2019–27.
- 56 Finis D, Hayajneh J, König C, *et al.* Evaluation of an automated thermodynamic treatment (LipiFlow): system for meibomian gland dysfunction: a prospective, randomized, observer-masked trial. *Ocul Surf* 2014;12:146–54.
- 57 Doan S, Chiambaretta F, Baudouin C. Evaluation of an eyelid warming device (Blephasteam) for the management of ocular surface diseases in France: the ESPOIR study. *J Fr Ophthalmol* 2014;37:763–72.
- 58 Aghai ZH, Kode A, Saslow JG, *et al.* Azithromycin suppresses activation of nuclear factor-kappa B and synthesis of pro-inflammatory cytokines in tracheal aspirate cells from premature infants. *Pediatr Res* 2007;62:483–8.
- 59 Li DQ, Chen Z, Song XJ, *et al.* Stimulation of matrix metalloproteinases by hyperosmolarity via a JNK pathway in human corneal epithelial cells. *Invest Ophthalmol Vis Sci* 2004;45:4302–11.
- 60 Knop E, Knop N. [Meibomian glands : part IV. Functional interactions in the pathogenesis of meibomian gland dysfunction (MGD)]. *Ophthalmologe* 2009;106:980–7.
- 61 Baudouin C. [Revisiting meibomian gland dysfunction]. *J Fr Ophthalmol* 2014;37:757–62.